

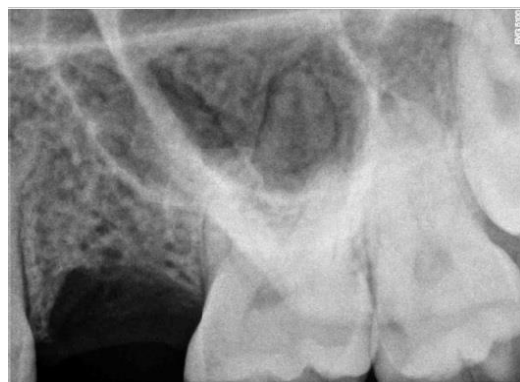# Minimal Invasive Sinus Elevation procedure: bone stability up to 5 years.

POSTER  
N° 75

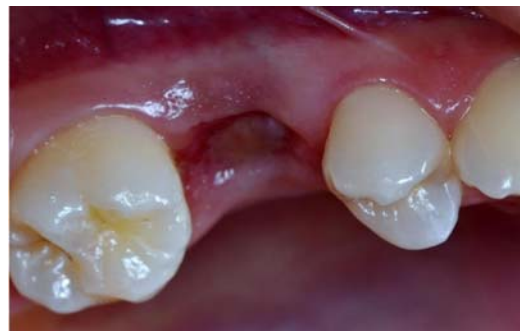ROMANO Francesco\*

## BACKGROUND

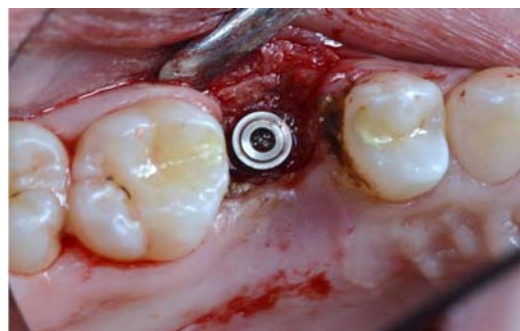
When the bone of edentulous alveolar ridges located in the posterior sites of the maxilla is not sufficient, because of the proximity of the Sinus, an elevation of the membrane is required to create the suitable space to implant with a predictable rate of success. Due to less morbidity, some transcrestals procedures are recently increasing in usage among clinics. Nevertheless, not all of them are always predictable or are leading to the same regenerative results.



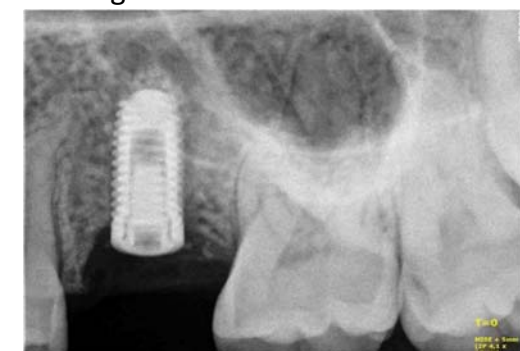1. Site before surgery



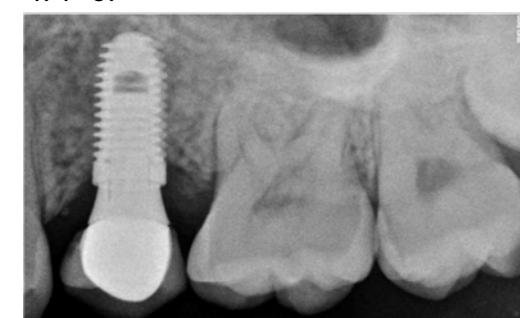2. Clinical view of the site before surgery



3. The 10 x 4,1 mm fixture inserted in 4 mm high bone residual crest.



4. T=0.



6. T= 3 years

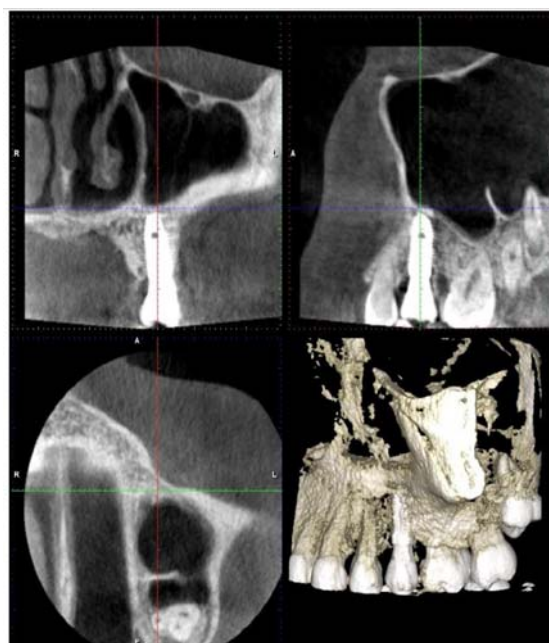
## CASE PRESENTATION

One delayed post extractive implant (Bone System, Milan), 10 mm x 4,1 was inserted in #65 in a 27 y.o. female patient.

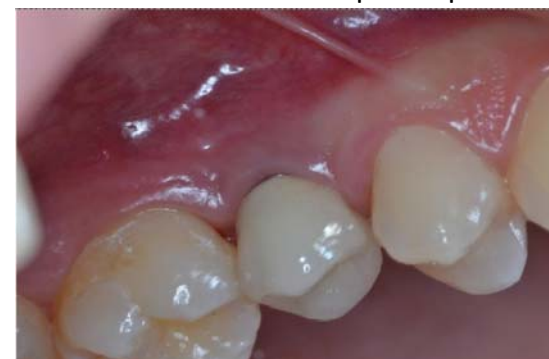At T=0 the residual bone crest was 4 mm high. After elevating a full thickness flap, the insertion has been done according to the MISE procedure (G. Carusi) where the sinus membrane is gently elevated by a Bio material (in this case, Collagen and B-TCP) pushed up by the same implant during insertion. The flap was sutured as usual and the suture removed after 7 days.

After 6 months the implant was uncovered and protésized as usual. After the first year the patient has been followed up each 6 months for 5 years. The measurements of the bone gain has been made by rx endo at 6 months and by CTCB, after 1 year. After that, the control was annual, clinically and radiographically checked by rx endo. The evidence of the generation of a high quality bone all around the implant and beyond the implant apex, between implant and Sinus Cortical bone has been of + 8mm, creating a 2 mm thick and stable bone also beyond the implant apex.

This is the usual result in 30 similar clinical cases treated in the last 5 years.



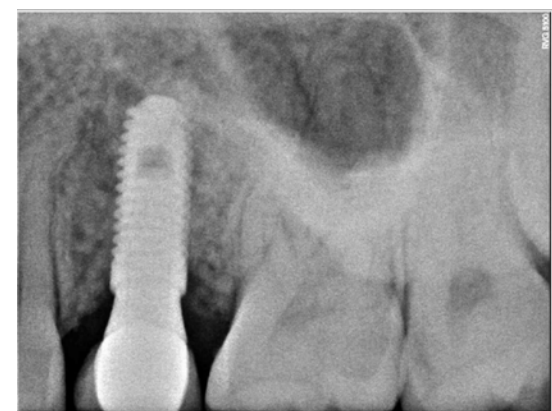5. CBCT at 1 Year after surgery. Note the 3D cortical bone regeneration obtained also over the implant apex



8. Clinical aspect after 5 years

## CONCLUSIONS

Even if short implants are having an increasing success in Clinical practice, the possibility to regenerate the proper quantity of bone sufficient to insert at least a 10 mm fixture, must always be seriously considered by the Clinician. The MISE can provide high quality and quantity of bone in these situations. It is an easy technique, not so dependent by the Surgeon's ability, and which provides very good results when it is correctly performed, also with only a size of 2-3 mm residual bone crest.



7. T = 5 years. Note the fixture surrounded by natural regenerated bone all around and beyond the apex.

## BIBLIOGRAPHY

- Carusi G., Salin M., Scilla M., Tecnica MISE (Minimal Invasive Sinus Elevation). Procedure chirurgiche. Ed. EDRA, 2016.
- Tatum, H. Jr (1986) Maxillary and sinus implant reconstruction. Dental Clinics of North America 30: 207–229.
- Bruschi, G.B., Scipioni, A., Calesini, G. & Bruschi, E. (1998) Localized management of sinus floor with simultaneous implant placement: a clinical report. The International Journal of Oral & Maxillofacial Implants 13: 219–226
- Lundgren, S., Andersson, S., Gualini, F. & Sennerby, L. (2004) Bone reformation with sinus membrane elevation: a new surgical technique for maxillary sinus floor augmentation. Clinical Implant Dentistry & Related Research 6: 165–173.
- Spinato S, Bernardello F, Galindo-Moreno P, Zaffe D. (2015) Maxillary sinus augmentation by crestal access: a retrospective study on cavity size and outcome correlation. Clin. Oral Impl. Res. 26,1375–1382